

Comparison of the Cutaneous Thermal Signatures Over Twenty-Four Hours With a Picosecond Alexandrite Laser Using a Flat or Fractional Optic

Emil A. Tanghetti MD^a and Danielle M. Tartar MD PhD^b

^aCenter for Dermatology and Laser Surgery, Sacramento, CA

^bUniversity of California, Davis, CA

ABSTRACT

Introduction: This study explored immediate heat signatures with different passing techniques and the delayed thermal data points with the picosecond Alexandrite laser with the 6mm flat and fractional optic during and after treatment. We sought to clarify the immediate effects of heating and understand the thermal and short term clinical difference when using these optics.

Results: There were no immediate differences or a significant temperature rise with different passing techniques using the flat or the fractional optic. However, after treatments a significant temperature elevation over 24 hours with manageable erythema was noted with the fractional optic. Only faint redness was appreciated with the flat optic.

Conclusion: The different passing methods with these optics did not result in a significant thermal change. However, the fractional optic produces a localized area of epidermal necrosis which results in a significant clinical and a delayed thermal effect. With multiple treatments over time, collagen, elastic tissue, and mucin is produced resulting in improvement of acne scars and photo-damaged skin. This process suggests that a well-placed epidermal injury can stimulate an inflammatory cascade with dermal remodeling.

J Drugs Dermatol. 2016;15(11):1347-1352.

INTRODUCTION

Picosecond devices were commercially introduced a number of years ago to better treat tattoos and pigmented lesions. The picosecond Alexandrite laser effectively treats most tattoos. Difficult to treat green ink shows the most dramatic rapid clearing with this device. The absorption of 755 nm light by melanin also makes this laser an excellent treatment for Nevus of Ota and other pigmented lesions.

The fractional optic was introduced for use in facial rejuvenation, abnormal pigmentation, and acne scars. Brauer and colleagues reported improvement in acne scars associated with new collagen, tissue and melanin after a series of treatments.¹ Our center was the first to characterize the histological changes induced by this fractional optic. We observed intra-epidermal vacuoles located in the stratum granulosum of the epidermis measuring approximately 60 microns in diameter.^{2,3,4}

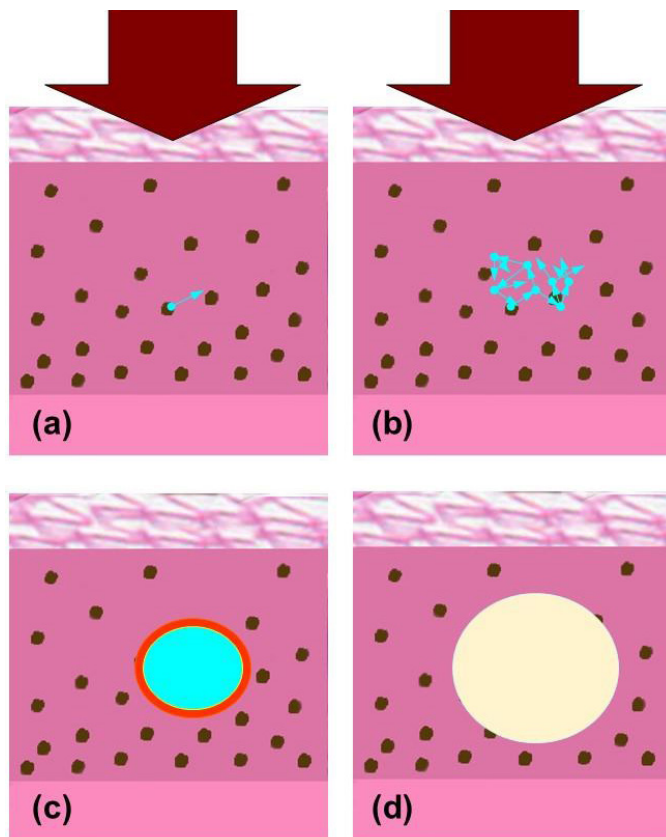
This localized zone of intra-epidermal injury was observed in individuals who had a melanin index (MI) of greater than 15, as measured by skin pigmentation meter (Skintel™) and who were skin type II or greater. This correlates with an individual who has some degree of epidermal pigmentation. We postulated that this injury is the result of laser induced optical breakdown (LIOB).⁴ This fractional delivered laser energy light appears to be absorbed by melanin creating a situation where one or more free electrons are generated (Figure 1). The number

of free electrons grows in an avalanche process. A plasma region is created which absorbs energy from the laser pulse. The localized area of plasma generates heat to create a localized steam bubble. Histology taken within minutes after treatment reveals a vacuole created by the damage (Figure 2). There is very little damage noted by microscopy to the surrounding keratinocytes. At 24 hours, this void is filled with rehydrated (Figure 3) cellular debris which stains positively with Fontana Mason indicating the presence of melanin (Figure 4). Over the next three weeks the vacuole contracts and forms a zone of microscopic epidermal necrotic debris (MENDS), which is exfoliated (Figure 2).

In low melanin individuals with skin type I and II, there is a different clinical picture and histology. Scattered hemorrhagic papules are sometimes seen with the highest energy settings. Histology reveals scattered areas of dermal hemorrhage often associated with vacuoles filled with red blood cells at the dermal/epidermal junction suggesting absorption of this high energy light by hemoglobin.⁴

This device has been safely and effectively used for facial rejuvenation and acne scars in darker skin types. These epidermal vacuoles are seen with all commercially available spots 6mm (.71J/cm²), 8mm (.40J/cm²), and 10mm (.25J/cm²). The size of these vacuoles decreases as the energy decreases with the use

FIGURE 1. Process of vacuole formation in the epidermis: (A) High intensity portion of the laser beam created by the diffractive lens array irradiates a region of the skin. A seed electron is ejected from an absorber (melanin). (B) The number of free electrons grows in an avalanche process. Electron plasma density increases absorbing energy from the beam. (C) The laser beam terminates leaving a hot plasma ball. The plasma ball heats the surrounding tissue above boiling temperature. (D) Steam expansion creates a vacuole in the epidermis containing cellular debris.



of larger spots.⁴ The injury is confined to the epidermis and does not appear to disrupt the basement membrane.

Discussion of devices for facial acne scars have often centered on the concept of dermal wounding as a necessary part of the process. Many have advocated that deeper wounding results in better clinical outcome.⁵ However, Orringer and others have questioned the concept with clinical and laboratory investigations demonstrating good outcomes with more superficial wounding.⁶ The histology and clinical findings with the picosecond Alexandrite laser and the fractional optic strongly suggest a well-placed epidermal injury could result in dermal remodeling.

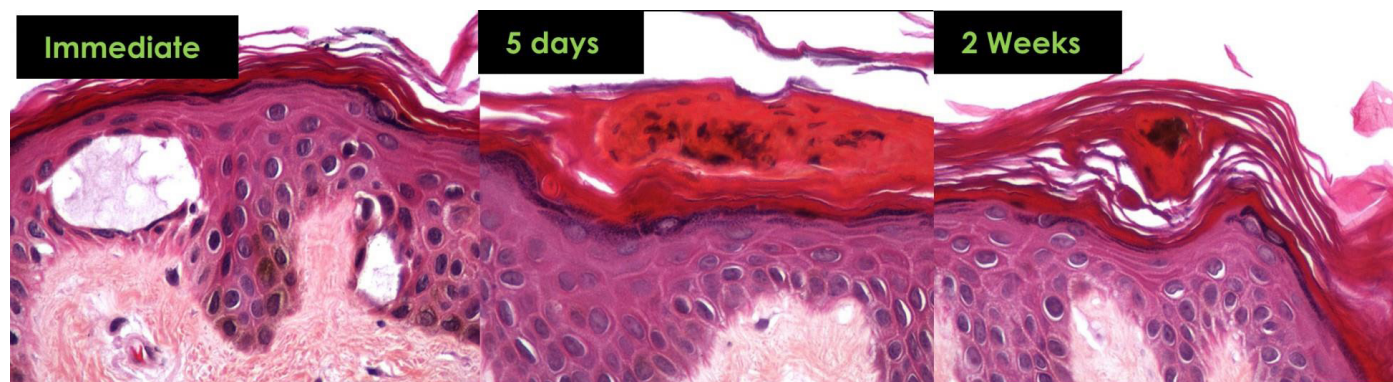
This study explored the immediate heat signatures with different passing techniques and the delayed thermal data points with the picosecond Alexandrite laser by using 6mm flat and fractional optic during and after treatment. We hoped that this would offer a clear understanding of the immediate effects of heating and some insights to the pathophysiological mechanism associated with improvement that we are seeing with this device and the fractional optic.

MATERIALS AND METHODS

A 755 nm picosecond Alexandrite laser with a 6 mm diffractive lens array optic (Picosure,™ Cynosure, Westford, MA) and the 6mm flat optic were used to treat a 10 cm by 10 cm area of skin on the arm and abdomen of volunteers. A FLIR thermal camera model Thermo Vision A320 was used to document the temperatures during and after the treatments. We attempted to characterize the temperature changes with four consecutive passes over the treatment area versus four passes with 1 minute in between individual passes. Temperature time points and photography were documented immediately, 15 minutes, ½ hour, 1 hour, 2 hours, 4 hours, and 24 hours after treatment.

The flat optic provides a uniform treatment with a 6mm spot diameter. The diffractive lens array consisted of closely packed individual hexagonal lenses with 500 µm pitch, the center-to-center lens distance. This lens array will also be referenced to as the fractional optic in this paper for it does deliver the laser

FIGURE 2. Intra-epidermal vacuole in skin with FST III, MI = 23 measuring approximately 60 microns in diameter. Biopsy performed 10 minutes post treatment.



© 2016-Journal of Drugs in Dermatology. All Rights Reserved.

This document contains proprietary information, images and marks of Journal of Drugs in Dermatology (JDD).

No reproduction or use of any portion of the contents of these materials may be made without the express written consent of JDD.

If you feel you have obtained this copy illegally, please contact JDD immediately at support@jddonline.com

FIGURE 3. Histology from a skin biopsy at 24 hours in a Hispanic patient skin type IV, MI = 31 on non sun-exposed skin demonstrating intra-epidermal vacuoles containing cellular debris with treatment fluence 0.71 J/cm² (6mm spot with fractional optic).

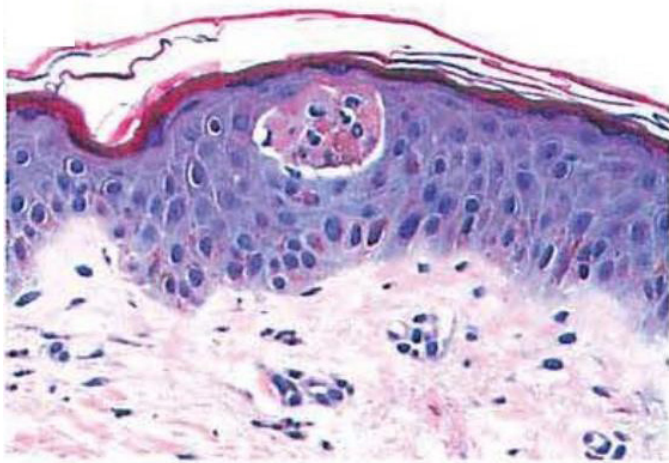
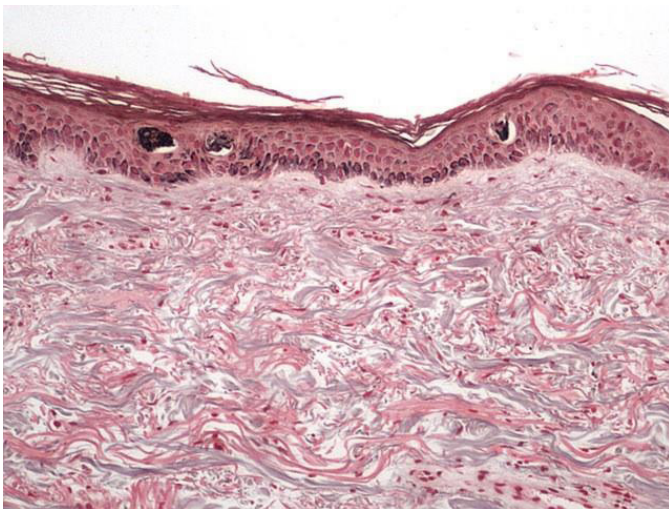


FIGURE 4. Fontana Masson staining for melanin in skin type III, MI=23 at 24 hours post treatment. Note the increased density of this staining in the vacuoles along with cellular debris. The underlying melanocytes, basal cells and adjacent epidermal cells appear intact.




light in a fractional manner. This lens array modifies the intensity profile of the picosecond Alexandrite laser beam to produce a hexagonal array of high intensity regions surrounded by low intensity background. Approximately 70% of the total energy is delivered in the high fluence regions comprising less than 10% of the treated area for a single non-overlapping pass. The remaining 30% of the energy provides the low fluence background. (Figure 5a, 5b)

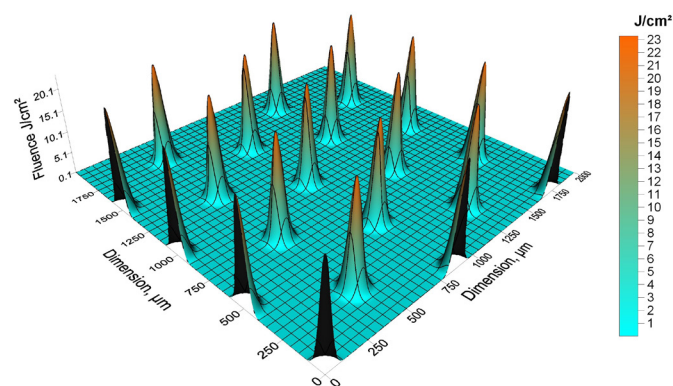
Both the flat and the fractional lens array optic are set to deliver the same total energy in the treatment spot size, 0.71J/cm² in a

FIGURE 5. (A) This diffractive lens array is referred to as fractional optic. It is a hexagonal close packed array with 500µm center-to-center spacing. The average fluence is 0.7J/cm² with a 25mm lens array distance to the skin. (B) Fluence distribution in the treatment plane on the skin surface. Treatment spot size 6mm, average fluence setting 0.71 J/cm². 70% of total energy is delivered through micro spots; remaining 30% results in low fluence background; less than 10% of the tissue is exposed to high fluence.

(A)



(B)

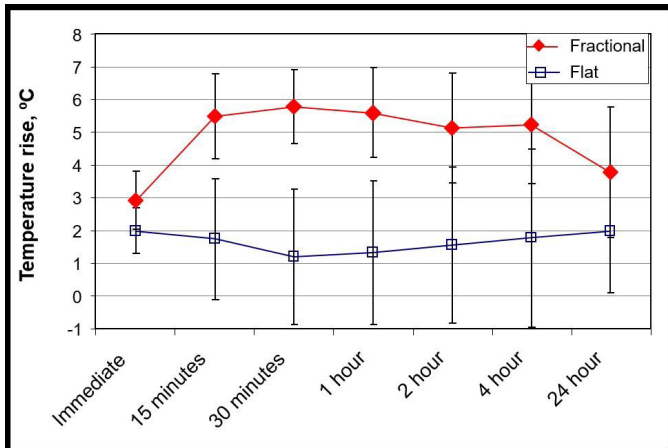


6mm spot diameter. The only difference between the two optical delivery systems is the energy distribution in the treatment spot. The flat optic delivers a uniform energy distribution. The fractional lens array optic delivers an arrangement of high intensity regions embedded in a low intensity background (Figure 5a, 5b).

RESULTS

There was no significant temperature rise immediately during treatment with either optic. The different passing techniques,

FIGURE 6. Mean temperature rises above baseline observed post treatment with the fractional and the flat optic. Solid symbols indicate statistical significance ($P<0.05$). Open symbols indicate lack of statistical significance at the 0.05 level.



four consecutive passes or four passes with a minute delay in between passes, did not reveal a significant temperature elevation with the two passing methods.

Beginning at the first time point 15 minutes after treatment, the area treated with the fractional optic showed a greater temperature rise from baseline than did the flat optic. At 1 hour after treatment an average temperature rise of 5.6 degrees centigrade elevation from baseline was observed with the fractional optic and at 24 hours this was noted to persist with an average 3.8 degrees centigrade elevation from baseline (Figure 6). The Dunnett's test was used to test the statistical significance of the mean temperature rises above baseline at each time point. All of the mean temperature rises observed after treatment with the fractional

optic were statistically significant ($P<0.05$). These findings were accompanied by an erythematous urticarial response beginning at 15 minutes and evolving into noticeable, but manageable erythema at 24 hours which could be covered by make-up (Figure 7).

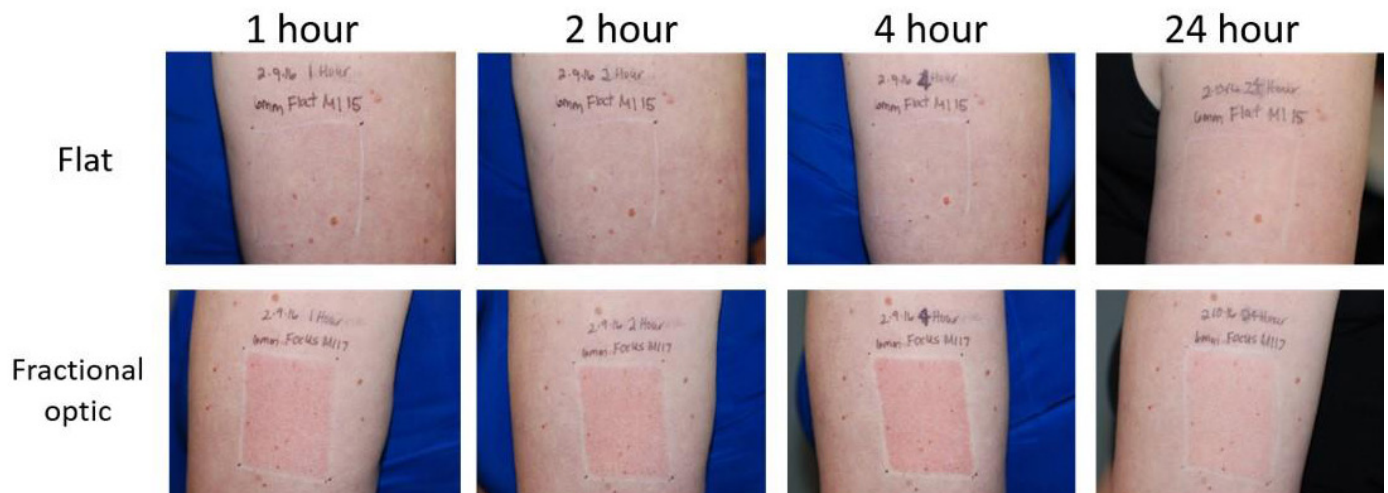In contrast, the flat optic showed a temperature rise of 1.3 degrees centigrade at one hour after treatment. The Dunnett's test of the mean temperature rises observed after treatment with the flat optic did not show statistical significance at the 0.05 level. Clinically, only faint erythema, which quickly resolved, was observed at 1 hour after treatment (Figure 7).

The mean of the differences between the temperature rises above baseline for each patient using the fractional and the flat optic was noted as 4.2 degrees centigrade at 1 hour and 2.9 degree centigrade at 24 hours after treatment (Figure 8). The mean temperature rise differences above baseline were statistically significant from 15 minutes post treatment to 4 hours post treatment ($P<0.05$). The mean temperature rise differences immediately post treatment and at 24 hours post treatment were not statistically significant at the 0.05 level.

DISCUSSION

We initially conducted this study to investigate the difference in passing technique with the fractional optic. We used the flat optic as a comparator arm. There was not a significant temperature rise with either optic with consecutive passes versus a minute or longer in between passes. This should not be surprising since the relatively small amount of energy deposited in the skin is expected to lead to a very small temperature rise. The spatially average temperature rise in the epidermis following the laser pulse was calculated including the cooling in the surrounding tissue using the formalism outlined in.⁷ The calculated epidermal temperature rise caused by a laser pulse delivering

FIGURE 7. These photographs represent the treated areas with a flat and fractional optic over 24 hours.



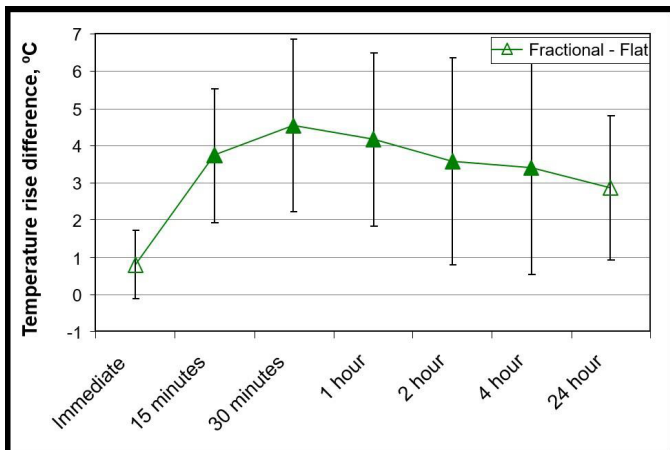
© 2016-Journal of Drugs in Dermatology. All Rights Reserved.

This document contains proprietary information, images and marks of Journal of Drugs in Dermatology (JDD).

No reproduction or use of any portion of the contents of these materials may be made without the express written consent of JDD.

If you feel you have obtained this copy illegally, please contact JDD immediately at support@jddonline.com

FIGURE 8. Mean of the differences between the temperature rises above baseline for each patient using the fractional and the flat optic. Solid symbols indicate statistical significance ($P < 0.05$). Open symbols indicate lack of statistical significance at the 0.05 level.



0.71 J/cm², the highest fluence in the study, was 0.5 degrees at 0.1 second after the laser pulse, 0.2 degrees at 1 second after the laser pulse, and 0.03 degrees at 1 minute after the laser pulse. However, we noted a distinct delayed difference clinically at the treatment sites after a few minutes between the two optics with more erythema and heat on the side treated with the fractional optic. This observation was the most interesting aspect of this study.

The histology does offer a clue to the difference seen in this study. The creation of the vacuoles in the epidermis is in stark contrast to the absence of microscopic changes observed with the flat optic with hematoxylin and eosin staining (Figure 9). While there might be some degree of heating and damage with the flat optic, there is not the well-defined epidermal damage and the striking delayed temperature rise seen with the fractional treatment. These findings suggest that this unique epidermal injury produces a cascade of mediators, which produce a delayed temperature rise and the ultimate generation of new collagen, elastic tissue, and mucin.

Our current array of ablative and non-ablative devices that are used for the treatment of acne scars all produce epidermal and dermal injury. In darker skin types this type of injury can produce areas of dyspigmentation due to damage to the dermal/epidermal interface. This type of post treatment problem can be avoided with 755 nm picosecond laser with the fractional optic.

We hypothesize that the delay in temperature elevation observed in skin following treatment with the fractional optic may be immune-mediated. While many mediators of immune response are released from the dermis post-injury, epidermal-derived mediators are less well-defined. One factor that is associated

FIGURE 9. Histology taken at 24 hours after treatment with a flat optic at 1.3 J/cm², MI 17 Skin Type III, Hispanic, non-sun exposed.

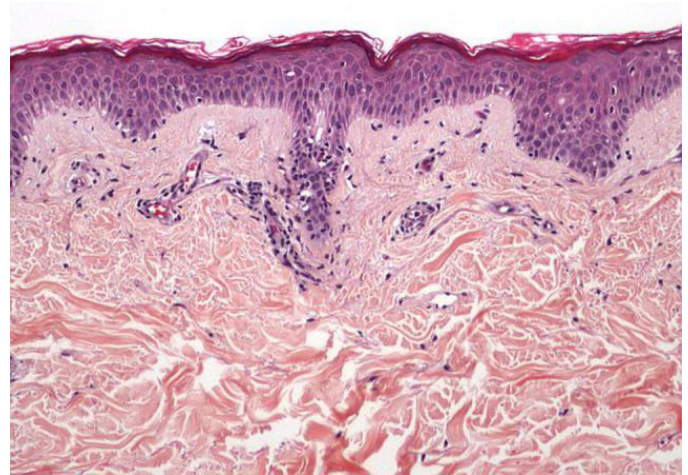
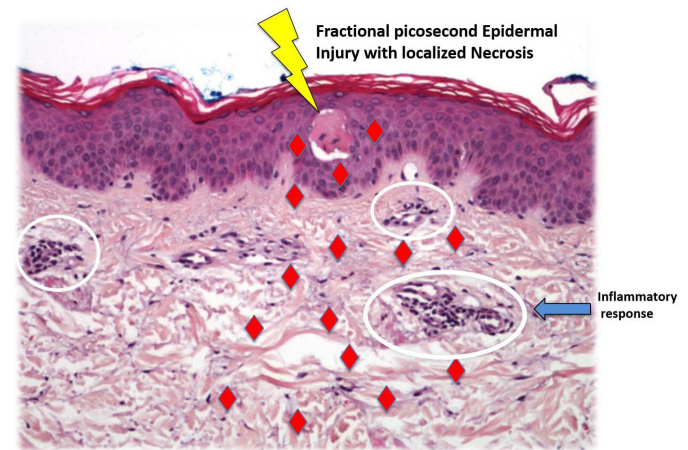


FIGURE 10. Epidermal injury and subsequent necrosis leads to cytokine release and delayed inflammation, resulting in dermal remodeling. ♦ = cytokines



with localized epidermal injury and a dermal response is Interleukin-33.⁸ This member of the IL-1 family is expressed by epithelial cells, including keratinocytes, and represents an endogenous danger signal that can be released in response to injury, damage or necrosis. IL-33 is then able to directly target cells of both the adaptive and innate immune response by binding the IL-1 family receptor ST2. In fact, IL-33 acts directly on T cells, dendritic cells, natural killer cells, and macrophages to promote inflammation. The laser-induced formation of the vacuoles with the picosecond device and the fractional optic results in epidermal injury, which could release IL-33 that is stored in the nucleus (Figure 10). This factor can diffuse into the dermis and function as a cytokine stimulating an inflammatory reaction, as well as up regulating cellular gene expression of fibroblast and other dermal cells to produce new collagen, elastic tissue, and

mucin. There are other mechanisms and other cytokines that also could be generated by this type of injury.

The rapid vacuole formation with the generation of an LIOB could create a pressure wave in the skin, which could also result in the initiation of dermal remodeling. This could initiate changes in cell signaling and the release of cytokines from alterations in cellular membranes.^{3,9} The hypothesis is based on the fact in during the formation of plasma.

CONCLUSION

The different passing techniques with the fractional and flat optic by the picosecond Alexandrite at 0.71J/cm² did not result in a significant thermal change. However, the fractional optic produces a localized area of epidermal necrosis, which results in a significant clinical and thermal effect. With multiple treatments over a period of time, new collagen, elastic tissue and mucin is produced resulting in improvement of acne scars and photo-damaged skin. This process suggests that a well-placed epidermal injury can stimulate an inflammatory cascade and dermal remodeling.

ACKNOWLEDGMENTS

This study was supported by research funding from Cynosure, Inc. in 2015.

DISCLOSURES

Dr. Tanghetti is a consultant and researcher for Cynosure, Inc. Dr. Tartar has no conflicts of interest to disclose.

REFERENCES

1. Brauer JA, Kazlouskaya V, Alabdulrazzaq H, et al. Use of a picosecond pulse duration laser with specialized optic for treatment of facial acne scarring. *JAMA Dermatology*. 2015; 151(3):278
2. Tanghetti E, Tanghetti M. A clinical and histologic study of skin treated with a pico-second alexandrite laser comparing a uniform treatment spot and a spatially modulated spot. *Lasers Surg Med*. 2014; 46:28
3. Tanghetti E. Characterization of the histologic changes in the skin from the treatment with the 755nm Picosecond Alexandrite Laser. *Lasers Surg Med*. 2015; 47(S26):24
4. Tanghetti E. The histology of skin treated with a picosecond alexandrite laser and a fractional lens array. *Lasers Surg Med*. 2016; (Epub ahead of print)
5. Henry Chan's discussion at controversies in laser medicine surgery. 2015
6. Oranger J.S, Rittie L, Baker, J.J, et al. Molecular mechanisms of non-ablative fractionated laser resurfacing. *Br J Dermatol*. 2010;163(4):757-767
7. Mirkov M, Sherr EA, Sierra RA, et al. Analytical modeling of laser pulse heating of embedded biological targets: an application to cutaneous vascular lesions. *J Appl Phys*. 2006; 99(11):114701.
8. Balato A, Raimondo A, Balato N, et al. Interleukin-33: increasing role in dermatological conditions. *Arch Derm Res*. 2016; 308(5):287-296
9. McDaniel D. Gene expression analysis in cultured human skin fibroblasts following exposure to a picosecond pulsed alexandrite laser and specially designed Focus optic. *Lasers Surg Med*. 2015; 47(S26):2

AUTHOR CORRESPONDENCE

Emil A. Tanghetti MD

E-mail:..... et@dermatologyandlasersurgery.com